IAPO Interamerican Association of Pediatric Otorhinolaryngology

XI IAPO Manual of Pediatric Otorhinolaryngology

Editors

TANIA SIH
ALBERTO CHINSKI
ROLAND EAVEY
RICARDO GODINHO

Coordinator
TANIA SIH

The Secrets of Pediatric Otoscopy

Carlos Ruah, Ezequiel Barros, Fernando Vilhena de Mendonça, Samuel Ruah, Michael Paparella

Introduction

Otoscopy remains the mainstay of otological diagnosis. Since it became available, it has been recognized that the otoscopic findings vary with age and with the intensity and type of illumination used [1] (**Figure 1**).

Initially, several authors described the morphological aspects of the pediatric otoscopy during the first year of life, in an attempt to find a pattern that allowed for a better interpretation of the findings [2-5] **(Figures 2 and 3)**

Figure 1. Chromolithographs drawn by Politzer to illustrate different otoscopic pictures of the normal TM seen 1 - with daylight, 2 – with light from a candle 3 – thick eardrum 4 – thinner eardrum allowing visualization of long process of incus and stapes.



Figure 2. McLellan's diagram of the normal eardrum during the first week of life (1961). Note the light reflexes on each side of the umbo which he called fireballs and the absence of the pars flaccida.

Later, clinicians attempted to find the accuracy of otoscopic methods by comparing subjective findings among several observers [6], the findings of otoscopy compared to otomicroscopy [7] , pneumatic otoscopy versus findings at myringotomy [8,9] and by comparing pneumatic otoscopy with tympanometry [10].

All these studies have shown that the accuracy of otoscopy is best if the

subject is an older child or adult, if the otoscopist is experienced and in the presence of an absolutely normal eardrum or a frankly abnormal one. Furthermore no method has shown to be ideal to evaluate the accuracy of otoscopy [11-13].

The normal otoscopic findings in children since birth are better understood if the development of the ear, both before and after birth, are kept in mind.

Figure 3. Jaffe et al.'s diagram of the normal eardrum of the newborn (1970). Note the absence of the pars flaccida and manubrium and the highlight of the lateral process of the malleus and umbo.



Development of the middle ear related to otoscopy

The development of the ear is not completed at birth. Changes in the color, transparency, position and mobility of the eardrum have been described in the normal, healthy full-term infant and during the first year of life [2,3,5].

Three main reasons have been suggested to explain these otoscopic changes. The **first** one relates to the presence of amniotic fluid in the middle ear which disappears usually by the third day of life [14] but may remain in small quantities beyond 70 days of age [15]. The **second** one relates to the presence of mesenchymal tissue in the middle ear, which is progressively reabsorbed up to around 1 year of age in the normal child [16]. It may, however, persist way beyond that age in the presence of recurrent or persistent otitis media [17,18] or in congenital anomalies of the ear [19]. The **third** one relates to changes in the eardrum itself, mainly at the level of the pars flaccid, posterior-superior quadrant of the pars tensa and umbo. All these areas will sustain major developmental changes in thickness, color and transparency as the mesenchyme between the epithelium and the mucosa differentiates or is reabsorbed during post natal growth [20].

During early embryogenesis, the middle ear is filled with mesenchymal tissue. By the thirteenth week of development, the primitive eustachian tube reaches the middle ear (**Figure 4**) and grows out 4 pouches (the anterior, medial, superior and posterior sacci) full of amniotic fluid, which will progressively invade the middle ear and reabsorb the mesenchyme [21] (**Figures 5 and 6**).

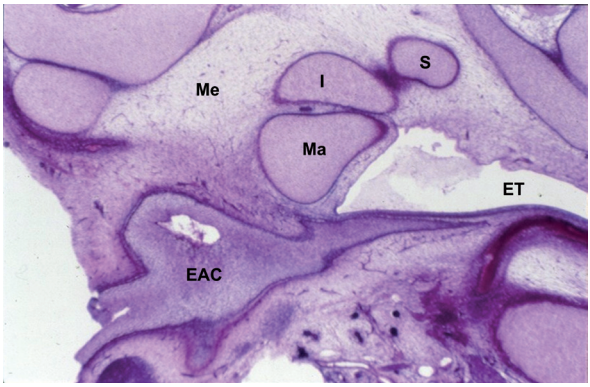

Figure 4 – Longitudinal section through the middle ear of a 11 week gestation human fetus. ET –primitive Eustachian tube. Me-mesenchyme. EAC- external auditory canal filled with the meatal epithelial plug. Ma-malleus. I-incus. S-stapes

Figure 5 – Progressive pneumatization of the middle ear through the 4 sacci. A-anterior. S-superior. M –medial. P-posterior.

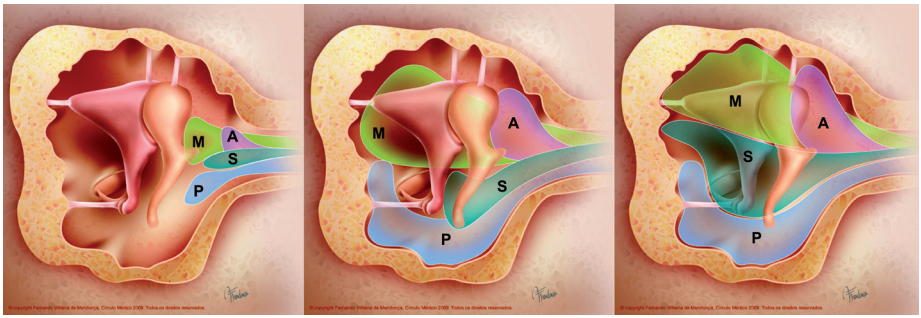

Figure 6 – Longitudinal section through the middle ear of a 22 week gestation human fetus. M-Malleus. I-incus. S-stapes. 1-eustachian tube. 2-anterior saccus. 3- posterior saccus. 4 – superior saccus. Note how thin is the anterior part of the eardrum (A) compared to the posterior part (B)

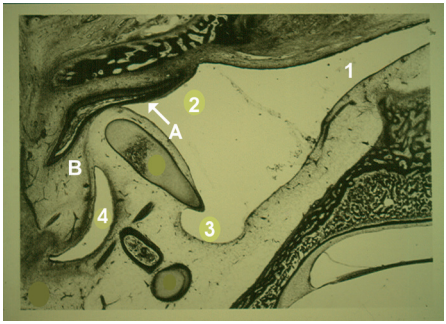

This occurs first in the anterior and inferior portions of the middle ear and then in its posterior and superior portions. This dynamic phenomena continues beyond birth and imprints progressive changes in the tympanic membrane and middle ear that are witnessed on otoscopy [22].

These include:

1. In the eardrum, its anterior half and the posterior inferior quadrant are very thin at birth and will change very little throughout life.
2. The posterior superior quadrant of the eardrum is extremely thick at birth, reddish in color, because it is filled with differentiating mesenchyme. It will thin progressively throughout life, but mainly during the first 2 years.

Due to the late arrival of the saccus medius to the attic, the appearance of the Prussak space starts only around birth and will develop throughout life but mainly during the first 2 years (**Figure 7**) [20].

Figure 7 – Longitudinal sections through the level of the pars flacida of human normal temporal bones at a) birth b) 5 days of age. c) 3 weeks of age d) 11 month of age e) 3 years of age.
P-Prussak's space

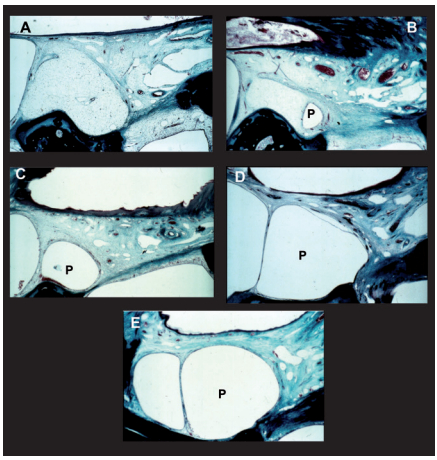

At birth, the tympanic membrane (TM) and bone make an angle of 30 to 35º with the horizontal plane. With growth of the head, the TM and bone are pushed laterally and vertically. Although the plane of the TM is quite vertical at the age of 4 months, its adult position is reached at the age of 3 years [23]. This change in position may justify the different light reflexes seen in otoscopy as the child grows.

The study of the vascular pattern of the tympanic membrane has been done in fetuses[24] and may be compared to a wheel in which the rim is made up of the tympanic branch of the maxillary artery and the stylomastoid branch of the posterior auricular artery. The spokes of the wheel are made of the anastomotic branches that radiate from the vascular arch that descends from the roof of the external auditory canal along the handle of the malleus and around the umbo. These anastomotic branches form vascular micromesh (small vessels) in the anterior quadrants and the posterior inferior quadrant of the eardrum which is barely seen through the naked eye. In the posterior superior quadrant, the anastomotic vessels are larger and form a vascular macromesh, which is easily seen. It is this developing macromesh that gives a reddish color to the normal posterior superior quadrant of the newborn eardrum.

The interpretation of otoscopy

Keeping the development of the ear in mind, 25 tympanic membranes from 16 healthy children from 24 hours of age up to seven years of age were photographed [22]. To be eligible, these children had to have an Apgar greater than 8 in the first minute and 10 at five minutes, visualization of the eardrum did not require any cleaning of the external auditory canal, otoscopy was considered normal by the first two authors and they all had normal hearing screenings. Representative samples of these pictures are printed below (**Figures 8, 9, 10, 11, 12 and 13**).

Figure 8- Otoscopic picture of a 1 week old child with 38 weeks gestation. The first structure that should be identified is the lateral process of the malleus. The Prussak space does not exist at this stage and the external auditory canal seems to end in the pars tensa. The posterior superior quadrant is red due to the development of the larger vessels in this area, thick because it is histologiacally filled with differentiating mesenchyme, and does not allow the visualization of the manubrium or any part of the ossicular chain

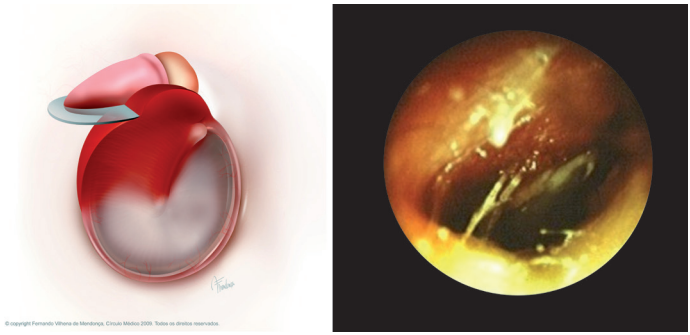

Figure 9. Otoscopic picture of a 5 day old child with 40 weeks gestation. The lateral process of the malleus is more clear. The Prussak space is just starting to appear and the posterior superior quadrant is less red and slightly thinner. The manubrium is still not defined

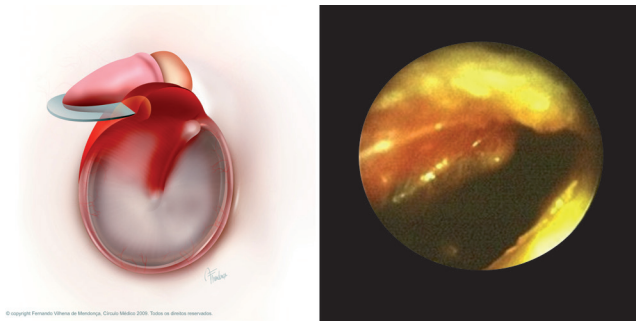

Figure 10 – Otoscopic picture of a 6 month old child. The pars flaccid is slowly becoming apparent, the lateral process of the malleus, the manubrium and umbo are clearly defined and the posterior superior quadrand is still thick, opaque and less red

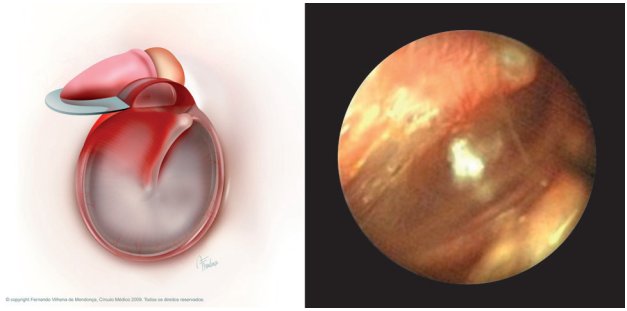

Figure 11 – Otoscopic picture of a 10 month old child. The pars flaccid is clearly seen due to the growing Prussak space. The posterior superior quadrant is translucid and allows the visualization of the macromesh anastomotic vessels

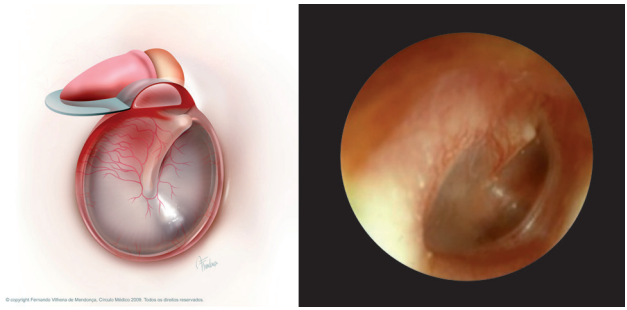

Figure 12 – Otoscopic picture of a 3 year old child. The pars flaccid and tensa are perfectly seen. The posterior superior quadrant has become sufficiently transparent and thin to allow visualization of the incus and stapes.

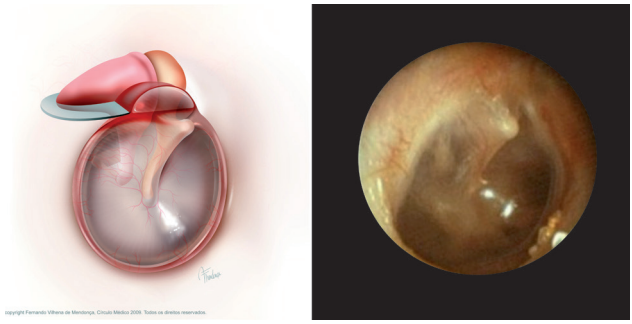

Figure 13 – Otoscopic picture of a 7 year old child, very much like the appearance of an adult one

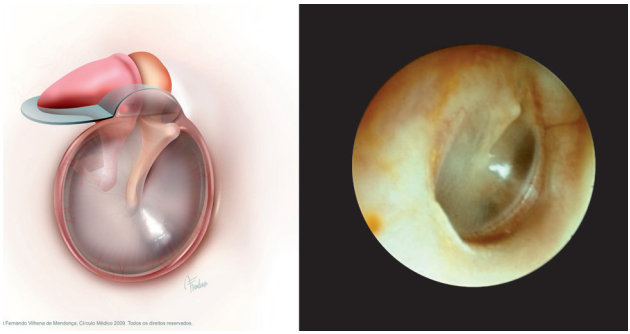

A color painting of the otoscopic picture was performed by an otolaryngologist who is also a medical illustrator (FVM), to help the interpretation of the findings. The findings at otoscopy are described in the legend of the pictures.

It is clear that the normal otoscopy during the first years of life mirrors the post natal development of the middle ear and drum.

References

1. Politzer A. The membrane tympani in health and disease illustrated by twenty four chromolithographs. Clinical contributions to the diagnosis and treatment of diseases of the ear with supplement. Tran Ba Huy P, Matheuson,. H G Newton in Classics in Modern Otology Garcia-Ballester L, Olague G, Ciges M editors Granada University press 1978.
2. McLellan MS, Webb CH. Ear studies in the newborn infant. J of Pediatrics 1961 58:4:523-527.
3. Jaffe BF, Hurtado F, Hurtado E. Tympanic membrane mobility in the newborn with seven month follow up. Laryngoscope 1970 80:36-48.
4. Balkany TJ, Berman SA, Simmons MA, Jafek BW. Middle ear effusions in neonates. Laryngoscope 1978 88:398-405.
5. Cavanaugh RM. Pneumatic otoscopy in healthy full-term infants. Pediatrics 1987 79:4:520-523.
6. Margolis CZ, Porter B, Barnoon S, Pilpel D. Reliability of the middle ear examination. Israeli Journal of Medical Science 1979 15:23-26.
7. Holmberg K, Axelsson A, Hansson P, Renvall U. The correlation between otoscopy and otomicroscopy in acute otitis media during healing. Scandinavian Audiology 1985 14: 191-199.
8. Mains BT, Toner JG. Pneumatic otoscopy:study of inter-observer variability. J. Laryngol. Otol 1989 103:1134-1135.
9. Paradise JL, Smith CG, Bluestone CD. Tympanometric detection of middle ear effusion in infants and young children 1976 58:2: 198-210.
10. Gimsing S, Bergholtz LM. Otoscopy compared with tympanometry. J. Laryngol. Otol. 1983 97:587-591.
11. Gates GA. Differential otomanometry. Am J. Otolaryngol. 1986 7:147-205.
12. Clarke LR, Wiederhold ML, Gates GA. Quantitation of pneumatic otoscopy. Otolaryngol. Head Neck Surg. 1987 96:119-124.
13. Cavanaugh RM. Pediatricians and the pneumatic otoscope: are we playing it by ear? Pediatrics 1989 84:2:362-364.
14. Roberts DG, Johnson CE, Carlin SA, Turczyk V, Kamuta MA, Yaffee K. Resolution of middle ear effusion in newborns. Arch of Pediatrics and Adolescent Medicine 1995 149:8: 873-877.
15. Northrop CC, Piza J, Eavy RD. Histological observations of amniotic fluid cellular content in the middle ear of neonates and infants. International Journal of Pediatric Otorhinolaryngology 1986 11:113-127.

16 – Takahara T, Sando I. Hashida Y, Shibahara Y. Mesenchyme remaining in humantemporal bones. Otolaryngol Head Neck <Surg. 1986 95: 349-357.

17. Paparella MM, Meyerhoff WL, Goycoolea MV. Silent otitis media. Laryngoscope 1980 90:1089-1098.
18. Ruah CB, Schachern P, Paparella MM; Zelterman D Mechanisms of retraction pocket formation in the pediatric tympanic membrane. Arch Otolaryngol Head Neck Surg 1992 118:1298-1305.
19. Takahara T, Sando I. Mesenchyme remaining in temporal bones from patients with congenital anomalies. A quantitative histopathological study. Ann Otol Rhinol Laryngol 1987 96:333-339.
20. Ruah C, Schachern PA, Zelterman D, Paparella MM, Yoon T. Age-related morphological changes in the human tympanic membrane. A light and electron microscopic study. Arch Otolaryngol Head Neck Surg 1991 117:627-634.
21. Spratley JE, Ruah CB. Embryology of the Ear. In Comprehensive Textbook of Otology. Diagnosis, management and oprerative techniques. Kirtane MV, Brackmann D, Borkar DM, de Souza C editors. Bhalani Publishing House, Mumbai India 2010: 21-35.
22. Ruah CB. Barros E, Ruah S, Penha RS, Schachern P, Paparella MM. Paediatric Otoscopy clinical and histological correlation J Laryngol Otol 1992 106:307-312.
23. Ars B. Organogenesis of the middle ear structures. J Laryngol Otol 1989 103:16-21.
24. Saini VK. Vascular pattern of human tympanic membrane. Arch Otolaryngol 1964 79:193-196.