Ossiculoplasty in Children: The Top Ten Rules List

Dustin Dalgorf, Tania Sih and Blake C. Papsin

Introduction

There is very little outcome data available for ossiculoplasty in children compared to that found for adult patients. There are only a few, albeit large, series in the literature and these report on children and adults together. This lack of specific information forces the pediatric otologist to rely on experience or apply adult data to children in their care. It is difficult to know whether it is appropriate to perform an ossiculoplasty in a child. Many treatment options are available such as observation with delayed repair, type III myringostapediopexy, primary or staged reconstruction, and bone-anchored hearing aids. The role of autografts and allografts is in children is also based on very limited data and published evidence.

Paediatric ossiculoplasty differs from that in adults in several ways. Firstly, the underlying cause is more likely to be a congenital anomaly or the result of cholesteatoma and CSOM plays a smaller role. Secondly, children are still growing. In the past, timing of ossicular chain reconstruction tended to be delayed until the onset of puberty. Lastly, audition and codification of language during the critical period of development is very important. For this last reason, paediatric ossicular chain reconstruction is approached aggressively.

Unfortunately, functional outcomes after this procedure vary greatly. This can be due to poor technical results. Other common complications include extrusion of the ossicular prosthesis, recurrence of middle ear disease or development of vestibular symptoms. Extruded prostheses are most often displaced laterally and dislodged from the oval window resulting in hearing deterioration. However, on some occasions, significant tympanic membrane retraction after ossiculoplasty may lead to intractable vertiginous symptoms because the prosthesis is forced medially placing increased pressure on the oval window. Recurrent middle ear cholesteatoma will cause hearing deterioration and the potential for residual disease greatly impacts the timing of ossicular chain repair.

Despite the potential complications, there are several important considerations that the surgeon can use as a guide to improve decision making and hopefully the functional outcome after paediatric ossiculoplasty and we have designated these

issues our top ten rule list for pediatric ossiculoplasty. The top-ten recommendations to achieve a successful ossiculoplasty; (1) ensure a clean and stable middle ear, (2) reconstruct ossicles under an intact tympanic membrane, (3) preferentially use an autologous graft repair, (4) "functionally bank" the incus where it might work, (5) the presence of the stapes predicts success, (6) use cartilage grafts to protect the drum from the prosthetic, (7) if you have to use a prosthetic graft titanium is the preferred material reconstruction, (8) provide a cartilage shoe for stability in the oval window, (9) traumatic ossicular chain disruption have the best functional results and (10) you must consider the stapes footplate before going to surgery.

Rule Number 1: Reconstruction must be performed in a clean and stable middle ear.

Figure 1 shows an example of a hydroxyapatite total ossicular replacement prosthesis (TORP) placed at the time of the patient's primary surgery for cholesteatoma. The prosthesis has been extruded and displaced in the hypotympanum with obvious cholesteatoma recurrence. Although, paediatric cholesteatoma is not necessarily more aggressive than equivalent disease found in adults, it is contained within smaller anatomy and thus more difficult to eradicate. It is particularly important to avoid a prosthetic reconstruction unless the middle ear is clean and stable. The only exception is in cases where the surgeon uses the incus as an autograft, which will be discussed later on in the chapter.

Figure 1. TORP placed at primary surgery now extruding with extensive cholesteatoma recurrence.

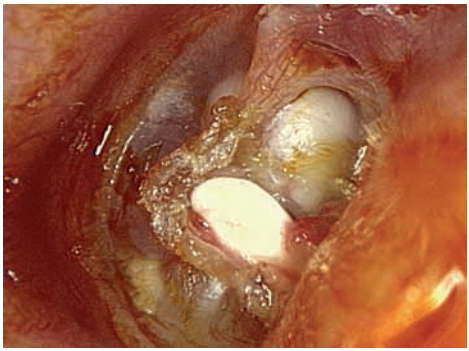

The approach to ossiculoplasty in children at our institution has evolved over the years. The primary goal is to maintain a clean and aerated middle ear space. In the past our decision tree was based on the age of the child (**Figure 2)** with puberty being a dividing line after which we could apply adult algorithms. If the child had passed through puberty, a second middle ear exploration was arranged and if there was no evidence of disease an ossiculoplasty would be performed at that time. If there was evidence of disease, a surgical revision would be continually performed until the child was free of disease. Only after the child's middle ear was clean and stable would ossiculoplasty be performed. If the child had not passed through puberty, a CT scan would be arranged one and a half years after surgery. If the middle ear space was clean and free of disease, ossiculoplasty was delayed until after puberty, while repeat surgical revision would be performed to resect recurrent disease.

Figure 2. Historical Algorithm for Paediatric Ossiculoplasty after Cholesteatoma.

Our current approach (**Figure 3**) has been modified for several reasons. Firstly, CT scans often miss disease. Secondly, waiting a period of one and a half years for a second middle ear exploration was too long and allowed more time for disease progression. Thirdly, delaying surgery until the onset of puberty does not seem to be based on any solid evidence. We are very aggressive with ossiculoplasty and from our experience, by the time a clean middle ear space is achieved the child is often approaching puberty not completing it. Essentially we will reconstruct any child with a clean and well aerated middle ear.

Figure 3. Current Algorithm for Paediatric Ossiculoplasty After Cholesteatoma

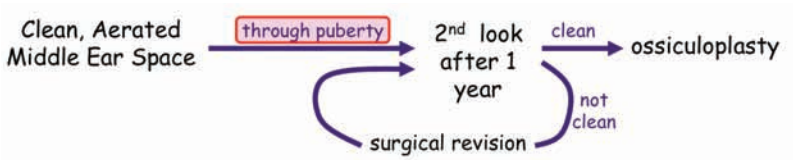

Rule Number 2: Intact tympanic membrane (**Figure 4**).

Figure 4. Two intact tympanic membranes are shown. In the picture on the left the incus is out of line and in the picture on the right the long process of the malleus is in line with the incus TORP

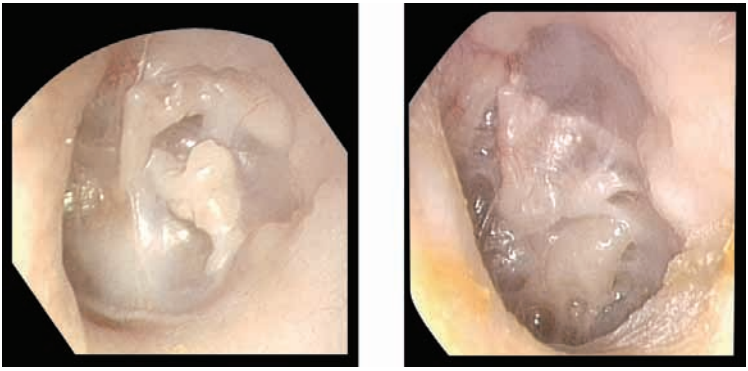

When performing an ossiculoplasty, it is vital to have appropriate tympanic membrane tension so you can size and fit the prosthesis. Tympanic membrane tension is the key to a successful ossiculoplasty. If a significant tympanic membrane repair is required, and especially if the repair will lie directly over the ossiculoplasty, you must perform the repair in a staged fashion. A tympanoplasty performed at the same time as an ossiculoplasty will not hold the ossicle reconstruction in place and will increase the risk of extrusion. In addition, too much pressure placed on the tympanoplasty graft will result in breakdown of the tympanic membrane.

However, as with most rules, there are exceptions. If the perforation is sufficiently distant from the intended site of ossicle reconstruction, a combined repair (tympanoplasty and ossiculoplasty) may be possible. Another situation where a concomitant repair is feasible is in the setting of an in-line malleus. An in-line malleus describes the alignment of the malleus over the stapedial superstructure. In this situation, tension is achieved through the under surface of the malleus.

Rule Number 3: It is preferable to use autologous bone

Autologous bone is advantageous over manufactured prostheses for ossicular chain reconstruction for several reasons including: lower cost, more efficient incorporation into the middle ear and the autologous bone grows with the child. The major disadvantage is the risk that the autologous bone may harbour residual disease placing the child at an increased risk of recurrence. In addition, there are some occasions where there is insufficient length of autologous bone to complete the repair.

Figure 5 shows an incus that has been fashioned into an optimal shape for ossicular reconstruction. The surgeon can strive to carve the bone into a small and fine structure, knowing that there is a prosthetic prosthesis available. The current state of ossicular prostheses offers an excellent alternative for repair if the incus should break while being shaped.

Figure 5. Autologous prosthetic: In this picture an autologous incus TORP has been prepared and placed in a footplate shoe of cartilage (which will be discussed in rule 8).

Rule Number 4. "Functionally bank" the incus

Implanting the incus under the skin or within the mastoid cavity was the common practice when I was being trained. The obvious disadvantage of this step is that locating the incus at a later date may be more difficult. We tend to "functionally bank" the incus by placing the autograft in its normal anatomical position on top of the stapes. This easily facilitates location of the incus in the correct position with minimal exposure at subsequent operations. In some occasions the incus will actually work. In this situation, if the patient demonstrates no evidence of recurrent middle ear disease the patient will receive the additional benefit of an intact ossicular chain negating the need for further procedures.

Rule Number 5: An intact stapes is the key to success.

The presence of an intact stapes predicts that the patient will achieve a good hearing outcome. An intact stapes offers the surgeon two reconstructive options. On the one hand, the incus can be removed, fashioned into an optimal shape and replaced to maintain ossicular continuity. On the other hand, with an intact stapes, the surgeon can remove the incus and perform a type III myringostapediopexy onto the head of the stapes. These patients achieve excellent hearing and avoid the complications of ossiculoplasty. **Figure 6** demonstrates a type III myringostapediopexy with the tympanic membrane placed on the stapes head and draped over the promontory.

Figure 6. Type III Myringostapediopexy Placed on an Intact Stapes

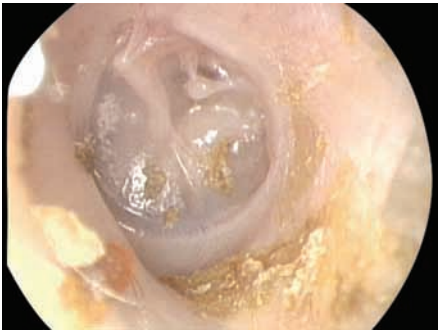

Rule Number 6: Use Cartilage grafts

The incorporation of cartilage grafts is an important part of the reconstructive process (**Figure 7**). Grafts provide support to the tympanic membrane and help to prevent atelectasis. Cartilage grafts also serve as another mechanism to help reduce or even eliminate extrusion of the prosthetic or autograft repair. Cartilage is readily available and easily harvested from a either the tragus or concha. There is a common concern among paediatric Otolaryngologists that the presence of a cartilage graft will negatively impact the child's hearing. If placed correctly, it has been our experience that the cartilage graft is an effective tool that provides support to the reconstructed ossicular chain without sacrificing the patient's hearing.

Figure 7. Cartilage graft overlying an ossiculoplasty in a child

Rule Number 7: Titanium is the preferred prosthetic material

There are many occasions when the surgeon is faced with a paucity of available autologous bone. Ossicles are often eroded, have insufficient length or being left almost completely destroyed. In these cases prosthetic material is the only reconstructive option for ossiculoplasty. In this situation, titanium is our preferred material. Titanium is an inert and biocompatible metal allowing integration into the middle ear. It offers a small mass resulting in good sound transmission. Titanium is easily modified and manipulated to achieve the appropriate size and shape. These cumulative properties effectively provide a robust repair. The Kurz-titanium prosthesis is most commonly selected for repair at our institution (**Figure 8**).

Figure 8. Titanium TORP prosthesis shown in place with a cartilage shoe holding it in the center of the oval window.

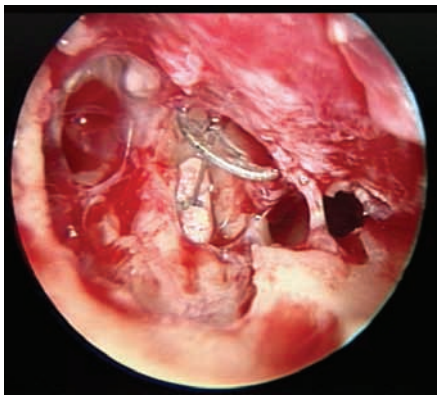

Rule Number 8: "The Cartilage Shoe"

Unfortunately, ossiculoplasty can immediately fail at the completion of surgery if the reconstructive prosthesis is dislodged. In the case of TORPs, this commonly happens upon closure when the foot of the prosthesis slips out of the oval window, ruining the repair by the time the patient is in the recovery room!

The cartilage shoe is an effective tool that can stabilize the prosthesis by providing direct positioning of the ossiculoplasty onto the oval window at its center (**Figure 8**). The foot of the ossiculoplasty is placed through cartilage shoe to maintain proper positioning long-term (Figure 5). Although it is designed for concomitant use with prosthetic repairs, the cartilage shoe may also be used during autologous bone reconstruction to provide added support. A shoe is fashioned out of cartilage with a hole in the middle. The incus is placed through the hole and the cartilaginous shoe is positioned over the oval window.

Rule Number 9: Traumatic ossicular chain disruptions have the best outcome

Although rare, children with traumatic ossicular chain disruption (**Figure 9**) tend to have the best post-operative functional outcomes following ossiculoplasty. These children often present with a transient conductive hearing loss due to the presence of hemotympanum or middle ear fluid. If this hearing loss does not improve within a six month observation period, the child should be taken to the operating room for middle ear exploration. Waiting longer than six months for traumatic hearing loss to resolve increases the risk of middle ear scarring. If the incus is dislocated it will not properly function unless the bone is removed and repositioned or a type III myringostapediopexy is performed. As long as the stapes is present, the child will likely achieve a good functional hearing result (see rule number 5).

Figure 9. These CT scans show cuts passing through the incudo-malleal joint and there is obvious dislocation of the joint in the middle ear on the left side (see arrow).

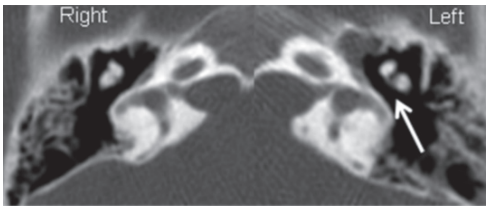

Rule number 10: You must consider the stapes footplate

Figure 10 depicts a normal appearing vestibule and basal turn of the cochlea with an oval window filled with bone. The patient has a fixed stapes footplate and repair of the ossicular chain in this situation is unlikely to be successful. At the time of ossiculoplasty we routinely try to elicit a round window reflex to ensure footplate is mobile. The oval window is gently palpated and the round window is observed to move in concert with the gentle footplate movements. Without this reflex, the patient will not likely benefit from an ossicular chain reconstruction. Performing an ossiculoplasty on a fixed stapes footplate may potentially result in further hearing deterioration but more commonly will result in no benefit after surgery. These children are best managed by surgeons that regularly treat conditions such as otosclerosis and have experience operating on the stapes. Similarly, patients with middle ear sclerosis may have a fixed stapes footplate and should be approached with extreme caution.

Figure 10. Fixed stapes footplate can be suspected based on the presence of bone throughout the entire oval window on high resolution CT scan.

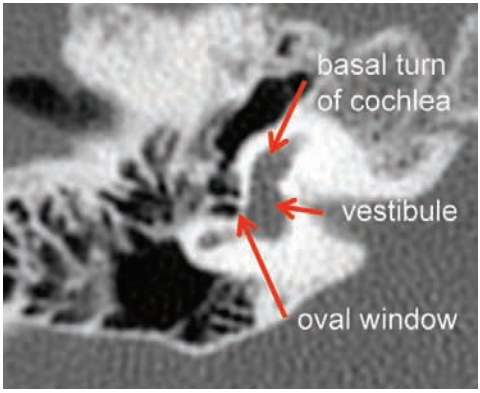

Conclusions

The functional results of ossiculoplasty are variable, difficult to predict, may not be durable and are operator dependent. It is important to consider the ten rules of pediatric ossicular chain reconstruction when making management decisions. The cause of hearing loss, appearance of the CT scan and current status of the middle ear, stapes and tympanic membrane will help to optimize the success of the repair.

Recommended readings

1. Michael P, Fong J, Raut V. Kurz titanium prostheses in paediatric ossiculoplasty--short term results. Int J Pediatr Otorhinolaryngol. 2008 Sep;72(9):1329-33.
2. Mishiro Y, Sakagami M, Kitahara T, Kondoh K, Kubo T. Long-term hearing outcomes after ossiculoplasty in comparison to short-term outcomes.. Otol Neurotol. 2008 Apr;29(3):326-9.
3. Daniels RL, Rizer FM, Schuring AG, Lippy WL.Partial ossicular reconstruction in children: a review of 62 operations. Laryngoscope. 1998 Nov;108(11 Pt 1):1674-81