Supraglottic Stenosis

Alan T. Cheng

Supraglottic stenosis refers to an abnormal narrowing of the larynx, extending from the tip of the epiglottis to just above the glottis (**Figure 1**), bounded by the surfaces of the epiglottis, the aryepiglottic tissues, arytenoid, corniculate and cuneiform cartilages, and the false vocal cords (vocal folds), and may involve the pharyngeal wall in this area. It is a condition that can be evaluated by examining the experience of others, and given the lack of numbers, it is **not** a subject that can be examined through a randomized control trial[1].

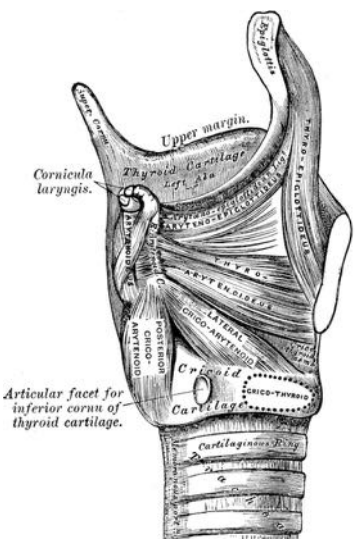

Figure 1. Anatomy of Larynx.

There are a variety of conditions that cause the tissues to obstruct the airway, producing signs and symptoms that reflect dysfunction. In general, it produces biphasic stridor, exertional dyspnoea, and evidence of respiratory distress including suprasternal tug, intercostal in drawing and increased work of breathing. The disease may involve external forces of the area, or involves the structures themselves. Excessive Bernoulli airflow only makes respiration worse.

Prevalence and causes

It is a relatively uncommon condition, but on looking through the literature, it is more prevalent than suspected. Since 1979, there have been 32 peer-reviewed articles on the subject, with 27 articles on the subject. There were 20 papers that described it with child subjects, whilst 7 articles involved only adult patients.

The major causative conditions that has been described include - 1) post supraglottoplasty from laryngomalacia surgery, 2) supraglottic stenosis/collapse from having long term tracheotomies, 3) laryngeal trauma from road accidents or prolonged intubation, 4) caustic injury to the larynx or 5) following surgery in conditions such as recurrent respiratory papillomatosis, epidermolysis bullosa, arytenoid prolapse after cricotracheal resection surgery.

Classification

The condition can be classified as being an **isolated** condition, or part of a **multilevel** obstruction. In multilevel pathology, it may be a result of a generalized laryngotracheal stenosis, whilst isolated conditions tend to reflect disease at the epiglottis only.

It may be **congenital** or **acquired** - with the congenital condition observed in some forms of severe laryngomalacia, especially those with the severe omega shaped supra glottis, which if not carefully surgically treated, can be made worse. As an acquired condition there are several causes as mentioned above, but the end result is still a pathological narrowing of the supraglottic airway.

In terms of time of onset, it may be classified as **acute** or **chronic**, with the former resulting from acute inflammatory events, whilst the latter results from insidious scarring over time.

Acute supraglottic stenosis refers mainly to epiglottitis or supraglottitis secondary to *Haemophilus influenzae* type B (**Figure 2**). It can also occur with caustic or inhaled burn injury. It is managed usually with operative intervention by establishing an artificial airway by endotracheal intubation or via a tracheostomy.

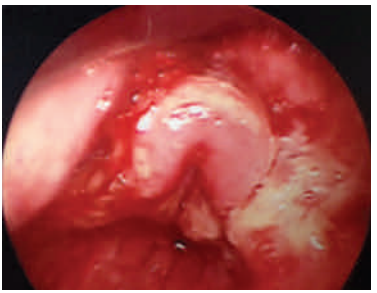

Figure 2. Epiglottitis associated with *Haemophilus influenzae* infection.

It is much less common since the introduction of the *Haemophilus influenzae* type B vaccine, with the prevalence dropping from 40-100 per 100,000 children down to less than 1 per 100,000 in the USA. In Australia, the vaccine was introduced into the routine schedule in 1993, and in 1992, the numbers recorded was 549 cases, a mortality rate of 10-15 cases in children < 6 years old. In 1994, the recorded cases dropped to 39 cases (www.ncirs.edu.au/immunisation/fact-sheets/hib-fact-sheet.pdf). Though there is obvious herd immunity, it is still seen amongst the older patient group (age 40-45 years) who did not receive the vaccination with a prevalence rate 2.5 times the current child rate, and can be responsible for significant morbidity and mortality in this age group. The treatment is with systemic antibiotics and consideration of early intubation if there is severe swelling of the arytenoid and aryepiglottic folds. Once the inflammation is on the improve with a satisfactory air leak, trial decannulation may be considered.

Chronic supraglottic stenosis comes in several forms, and my own experience of twelve paediatric cases and three adult cases, has taught me the need to understand the underlying cause before one is able to treat them appropriately.

Supraglottic stenosis can be associated with laryngotracheal stenosis with multi-level airway lesions involving the glottis, subglottis and the trachea (**Figure 3**). As highlighted by the experience from the Great Ormond Street Hospital for Sick Children [2,3], the use of an internal stent such as a Montgomery tube or an endotracheal tube has been the preferred modality. However, the resulting opening is often one which leaves the internal lumen relatively scarred, a poorer voice outcome, and potentially an airway that still may not generate a decent cough.

Figure 3. Supraglottic stenosis associated with multilevel laryngotracheal stenosis.

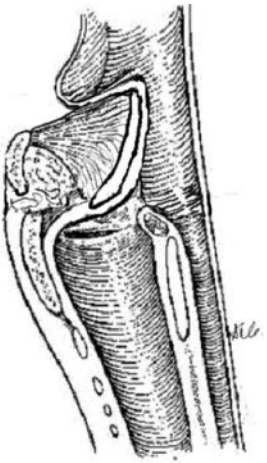

Figure 4. Supraglottic stenosis/collapse from long term tracheostomy and disuse dysfunction of the supraglottis.

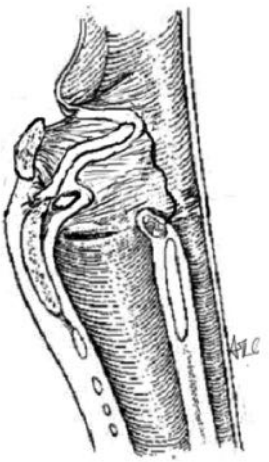

Figure 5. Epiglottic repositioning manoeuvre.

Supraglottic stenosis/collapse was originally described by Walner and Holinger[4] (**Figure 4**). It can be difficult to detect and may be a cause of failed decannulation following tracheostomy. We described a procedure of re-positioning the epiglottis, first described by Alarcon and Rutter [5]. By personal communication, we have used the same technique since 2005 in at least 10 cases to date, and published our initial results [6]. It is important to realize the mechanism of action of the supraglottic stenosis/collapse, and the factors producing the condition. The surgical management offered an improved airway in an anteroposterior direction, without affecting the lateral aspects of the supra glottis.

The key to this "epiglottic repositioning manoeuvre" is to debulk the tissue anterior to the epiglottis, in the pre-epiglottic space. I tend to detach the epiglottis at the petiole by initially marking the point with a needle, with a second surgeon guiding me endoscopically. This is followed by the use of a scalpel to divide at the epiglottic cartilage until I feel a release of the epiglottis from the petiole (**Figure 5**). We advise placement of at least two permanent sutures between the epiglottic cartilage, a hyaline cartilage that does not ossify, and the thyroid cartilage or hyoid bone. I complete the procedure by leaving a drain, in case of surgical emphysema or bleeding.

Supraglottic stenosis is a feared complication caused by supraglottic surgery for laryngomalacia or recurrent respiratory papillomatosis [7]. It can also occur with caustic ingestion, epidermolysis bullosa [8] (**Figure 6**), road accident trauma [9] .

The decisions made in this scenario highlights the need to be aware of this complication before surgery is undertaken, during the surgical procedure and at times of failed supraglottoplasty surgery.

The constrictive forces that narrow the supra glottis is usually where mucosal injury has occurred. It highlights a significant factor in mucosal healing. There are inherent genetic and loco regional factors in the mucosa of individuals that is sometimes difficult to ascertain, which determine whether a patient

Figure 6. Supraglottic stenosis following surgery to larynx with epidermolysis bullosa.

develops significant scarring following injury. Even though the clinician may attribute the failure of management to the "excessive" degree of mucosal excision, it is inherently the child's variable healing that determine the condition. In cases like these, it is important to utilise these factors to one's understanding in the management of the condition, as will be discussed below.

Management

Supraglottic stenosis can be a life threatening issue, and it is important to establish if the severity of the condition, and its progression. In some cases, the degree of stenosis is critical, and either intubating the airway or providing an alternative airway, such as a tracheostomy, to provide a safe airway is required.

Supraglottic stenosis occurs when the forces that hold the airway open is insufficient for the forces closing the airway, at the supraglottic level. It needs to be diagnosed, and in cases of supraglottic stenosis/collapse, it is readily missed by the laryngoscopist who stents the airway with the laryngoscope while the patient is under general anaesthesia. I mention the need for "diagnosis directed laryngoscopy". In the assessment, using a flexible bronchoscopy via the nasal passage in a patient spontaneously breathing in a supine position, the critically narrowed area is examined, whether it be at the petiole, or higher up in the supra glottis. Occasionally, a form of laryngomalacia is discovered, as seen in arytenoid prolapse following cricotracheal resection.

Scar bands may need to be released, and the supraglottis needs to function. Dis-use dysfunction of the supra glottis is seen in those tracheotomised, when airway is bypassing the glottis and supraglottis. The laryngeal muscles that provide tension that open the supraglottis are absent. The use of a stenting device is important in the initial reconstruction, whether it be a Montgomery stent, an endotracheal tube or the newer laryngotracheal moulds championed by Phillipe Monnier. Once the stent is removed, the patient needs to return to normal laryngeal function as soon as possible, allowing the tissues and muscles that dilate the supra glottis to function during respiration, deglutition and cough. The sensory mucosa of the area needs to be protected from ongoing inflammation, and it is necessary to minimise gastrointestinal refluxate and other inflammatory factors from preventing satisfactory healing. It is also important to understand the role of intra-lesional or systemic steroids, anti-biotic and anti fungal therapies, and adjuvant therapies such as mitomycin C and cidofovir, which may help minimise the recurrence of the underlying fibrosis or infective agents.

When dealing with the supraglottis, it is important to make sure to minimise the inflammation. The inflamed larynx pre-operatively is more likely to lead to failed surgery [5], and the following factors are said to be important in patient selection.
They include:

1) infection of the airway with either methicillin resistant *Staphyloccus aureus* or *Pseudomonas aeruginosa;*
2) excessive use of high dose steroids - which can adversely affect healing;
3) co-morbidities such as prematurity, long term ventilation, gastrointestinal disease, feeding disorders, neurologic impairment;
4) eosinophilic oesophagitis - as confirm on pre-operative oesophageal biopsies;

5) hidden airway lesions such as a type one laryngeal cleft, bilateral or unilateral vocal fold motion impairment, severe obstructive sleep apnoea, posterior glottic stenosis.

Surgical techniques to avoid supraglottic stenosis

In addition to optimising the laryngeal tissues prior to surgery, the techniques available to the practising surgeon need to be individualised to the case in hand.

1) Practise gentle mucosal handling –

a) When dealing with laryngomalacia and its various forms, it is becoming more apparent that the inflammation from using a CO_2 Laser can be unpredictable, making this tool less utilised for supraglottoplasty (**Figure 7**).

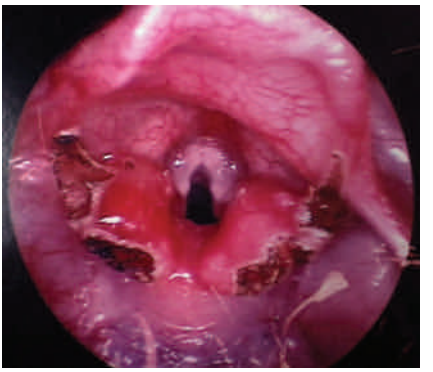

Figure 7. Laser surgery for laryngomalacia

b) There are also studies demonstrating the value of "unilateral" versus "bilateral" supraglottoplasty, confirming the long-term efficacy of the former procedure in managing severe laryngomalacia.

c) Using sharp instruments, gentle division of the short aryepiglottic folds, or limited excision of the prolapsing supra-arytenoid tissues are important lessons we provide our colleagues and ourselves.

d) Use of topical epinephrine or adrenaline to minimise bleeding, leaving sufficient mucosal coverage over excised areas and minimising exposed cartilage or perichondrium, hence minimising granulation formation

2) Change the vector of forces - The vector of forces involved in supraglottic stenosis may be also treated by:

i) Using noninvasive CPAP therapy [7] - nasal CPAP is becoming a frequently used tool in major Children's Hospital institution with an excellent temporising factor until the developing child's airway is sufficiently enlarged;

ii) Creating fibrotic scars that pull away the mucosa – as described by Zalzal [10] - Dividing the tissues external to the laryngeal introits may force the mucosa to evert outwards, using the natural scarring effects to maintain the laryngeal latency;

iii) Balloon dilate, inject with intralesional steroids, or apply mitomycin C, an antifibroblastic agent, usually at doses of 0.4-0.5 mg/ml for a period of at least 4- 5 minutes, to achieve the effective dose to work for at least 30 days, to counteract the 18-21 days it takes for normal respiratory mucosa to re-epithelise;

iv) Prolonged use of a Montgomery stent [2,3] has been useful in cases with generalised laryngotracheal stenosis, leaving a healed lumen above the vocal cords once the primary pathology is resolved

v) Epiglottic repositioning manoeuvre [5,6] as described above.

Conclusions

It is imperative that the paediatric otolaryngologist who treats children with all forms of airway narrowing, whether it be laryngomalacia or airway trauma, understand the pathophysiology of this condition. It should not be feared, but so long as one is aware of this possibility, and the forces that produce this condition, one can avoid making things worse by ignoring the co-morbidities that allows the patient's own inherent mucosal healing from developing supraglottic stenosis. When one has to tackle this condition, it is important to change the vector of forces that produce the condition in the first place from recurring. Be aware, be conservative but tackle the condition in a firm manner with the understanding of the underlying cause.

References

1. Stevens MS. Chang A. Simpson CB. Supraglottic stenosis: etiology and treatment of a rare condition. Annals of Otology, Rhinology & Laryngology. 122(3):205-9, 2013 Mar.
2. Bajaj Y. Cochrane LA. Jephson CG. Wyatt ME. Bailey CM. Albert DM. Hartley BE. Laryngotracheal reconstruction and cricotracheal resection in children: recent experience at Great Ormond Street Hospital. International Journal of Pediatric Otorhinolaryngology. 76(4):507-11, 2012 Apr.
3. Phillips PS. Kubba H. Hartley BE. Albert DM. The use of the Montgomery T-tube in difficult paediatric airways. International Journal of Pediatric Otorhinolaryngology. 70(1):39-44, 2006 Jan.
4. Walner DL. Holinger LD. Supraglottic stenosis in infants and children. A preliminary report. Archives of Otolaryngology -- Head & Neck Surgery. 123(3):337-41, 1997 Mar.
5. de Alarcon A, Rutter MJ. Revision pediatric laryngotracheal reconstruction. Otolaryngol Clin North Am. 2008 Oct;41(5):959-80
6. Varghese AM. Cheng AT. Epiglottic repositioning procedure for supraglottic stenosis/collapse. Annals of Otology, Rhinology & Laryngology. 120(7):478-83, 2011 Jul
7. Denoyelle F. Mondain M. Gresillon N. Roger G. Chaudre F. Garabedian EN. Failures and complications of supraglottoplasty in children. Archives of Otolaryngology -- Head & Neck Surgery. 129(10):1077-80; discussion 1080, 2003 Oct.
8. Chen YW. Lai SH. Fang TJ. Li HY. Lee TJ. Pediatric dyspnea caused by supraglottic stenosis: a rare complication of alkali corrosive injury. Arch Otolaryngol Head Neck Surg. 1997 Mar;123(3):337-41.
9. Oosthuizen JC. Burns P. Russell JD. Endoscopic management of posttraumatic supraglottic stenosis in the pediatric population. American Journal of Otolaryngology. 32(5):426-9, 2011 Sep-Oct.
10. Zalzal GH, Collins WO. Microdebrider-assisted supraglottoplasty. Otolaryngol Clin North Am. 1995 Aug;28(4):785-95.